

THE JOURNAL OF BONE & JOINT SURGERY

J B & J S

This is an enhanced PDF from The Journal of Bone and Joint Surgery

The PDF of the article you requested follows this cover page.

Acute gastric volvulus mimicking the cast syndrome: a case report

ME Ashby, GW Balfour and JA Campbell
J Bone Joint Surg Am. 1977;59:1101-1102.

This information is current as of November 2, 2007

Reprints and Permissions

Click here to [order reprints or request permission](#) to use material from this article, or locate the article citation on jbjs.org and click on the [Reprints and Permissions] link.

Publisher Information

The Journal of Bone and Joint Surgery
20 Pickering Street, Needham, MA 02492-3157
www.jbjs.org

Acute Gastric Volvulus Mimicking the Cast Syndrome

A CASE REPORT

BY MILTON E. ASHBY, M.D.*, GEORGE W. BALFOUR, M.D.*, AND
JOHN A. CAMPBELL, M.D.*, LOS ANGELES, CALIFORNIA

*From the Martin Luther King, Jr. General Hospital, Los Angeles,
and the Rancho Los Amigos Hospital, Downey*

Acute gastric volvulus has never been described as simulating the cast syndrome, in which the superior mesenteric artery causes an obstruction to the duodenum. It is generally believed that the same syndrome involving the mesenteric artery can be caused by prolonged hyperextension of the lumbar spine or recumbency with significant loss of body weight^{3,6-8,10,13,15,17,18}. Obstructive symptoms were reported to develop eight to twelve weeks after injury in patients who were bedridden because of serious injury and who did not have plaster immobilization or spine instrumentation¹⁸. These patients were designated as having the superior mesenteric artery syndrome.

Many other conditions may be responsible for duodenal obstruction. Measurement by aortography of the angle made by the superior mesenteric artery and the aorta as described by Mansberger and associates is the only way to make an unequivocal diagnosis.

The following case report is that of a patient who had

signs and symptoms of the cast syndrome developing after spine fusion for scoliosis. The diagnosis proved to be acute gastric volvulus, not the superior mesenteric-artery syndrome (cast syndrome). This entity has never been described previously as a complication to an orthopaedic operation.

Case Report

K. B., an eighteen-year-old severely mentally retarded woman with cerebral palsy, was first seen at the Martin Luther King, Jr. General Hospital on August 23, 1976, in the emergency room. She had been transferred from a nursing home because she had been vomiting for two days. Ten weeks previously, at the Rancho Los Amigos Hospital, the patient had had a spine fusion from the sixth thoracic to the fifth lumbar vertebra for a severe thoracolumbar scoliosis. Harrington instrumentation had been used, and a plaster body cast incorporating the left hip had been applied.

On admission from the emergency room, the patient was found to be critically ill with a pulse of 110 per minute, respirations of forty per minute, systolic blood pressure that was palpable at ninety millimeters of

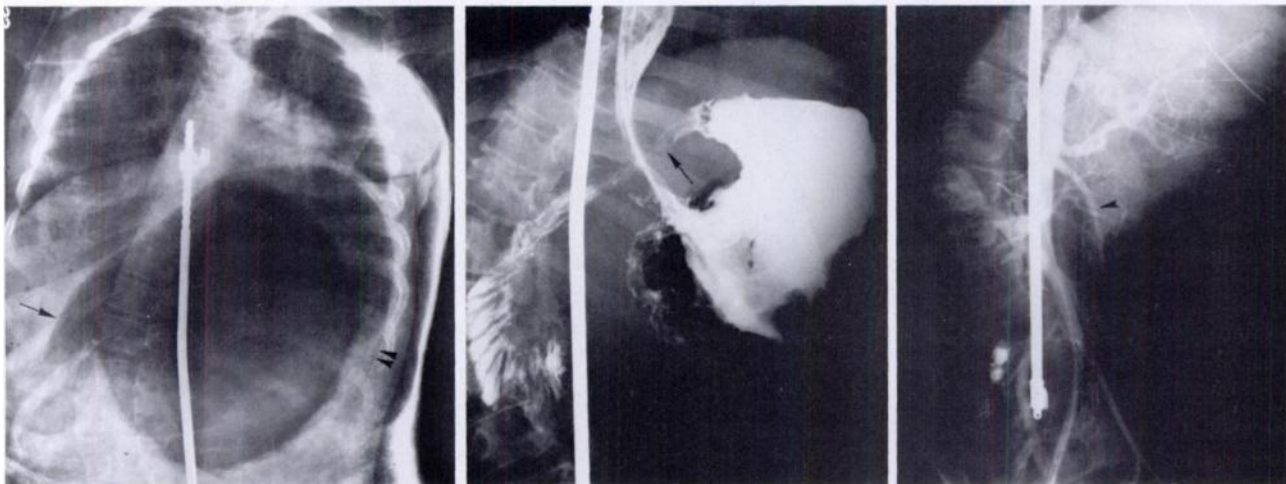


FIG. 1

FIG. 2

FIG. 3

Fig. 1: Gastric dilatation due to volvulus. Severe gastrectasis results when the volvular torsion of both the esophagogastric and pyloric ends of the stomach produce trapping of swallowed air. Note the so-called pyloric beak (single arrow) and the intramural diffusion of gas into the gastric wall (double arrows). The Harrington rod is visible as it bridges the scoliotic spine.

Fig. 2: Mesenteroaxial type of gastric volvulus. A nasogastric tube has reduced the torsion of the esophagogastric area and decompressed the stomach. Barium opacification of the stomach shows the antrum rotated above and to the left of the fundus. The torsion of the proximal part of the duodenum, causing incomplete obstruction of the gastric outlet, is visible (single arrow).

Fig. 3: Aortogram of gastric volvulus. The opacification of the superior mesenteric artery shows that its angle with the aorta is in excess of 30 degrees. This is thought to be insufficient to produce the superior mesenteric-artery obstructive syndrome, according to Mansberger and co-workers.

* Martin Luther King, Jr. General Hospital, 12021 South Wilmington Avenue, Los Angeles, California 90059.

mercury, and a temperature of 37.5 degrees centigrade. The patient, still in the body cast with the abdomen windowed, showed coffee-ground res-

idues of emesis about the mouth and face. Her eyes were dry and sunken, and her mouth and skin were dry. She had severely bitten both hands. The abdomen was markedly distended through the large anterior window. It was cyanotic, tender, extremely tight, and tympanitic. There were no audible bowel sounds. Plain roentgenograms of the abdomen disclosed a massive, single, long gas shadow (Fig. 1).

Initial serum chemistry studies included the following: urea nitrogen, forty-five milligrams per 100 milliliters; glucose, 230 milligrams per 100 milliliters; sodium, 146 milliequivalents per liter; potassium, 2.9 milliequivalents per liter; bicarbonate, 233 milliequivalents per liter; and chloride, ninety-four milliequivalents per liter. The hemogram showed the following: hematocrit, 46 per cent; hemoglobin, 15.6 grams per 100 milliliters; and white cell count, 6,900 per cubic millimeter. The blood gases were: PO_2 , fifty-six millimeters of mercury; and Pco_2 , forty millimeters of mercury. The serum pH was 7.39 and the bicarbonate, twenty-four milliequivalents per liter. The patient's weight on admission was twenty-five kilograms, and she was evidently considerably dehydrated.

The cast was removed and the patient was nursed on a Stryker frame. Nasogastric suction was instituted and intravenous fluid replacement was begun. Within thirty-six hours, the dehydration had disappeared (urea nitrogen down to three milligrams per 100 milliliters and hematocrit, 30 per cent), and the patient's abdominal signs and symptoms began to abate. On the second hospital day, an upper gastrointestinal contrast study revealed a gastric volvulus of the mesenteroaxial type (Fig. 2).

On the eleventh hospital day, an aortogram was done because we were not satisfied that the patient did not have the superior mesenteric artery syndrome. The superior mesenteric artery/aortic angle in this study was in excess of 30 degrees — that is, within normal limits according to Mansberger and associates (Fig. 3). Simultaneously, an upper gastrointestinal contrast study showed spontaneous resolution of the acute gastric volvulus.

On the twenty-fifth hospital day, the patient weighed thirty-two kilograms and a new body cast was applied, in neutral of spinal extension. Within twenty-four hours, she began to cry and vomit. Plain roentgenograms again showed gastric atony. All symptoms were relieved within forty-eight hours following nasogastric suction and removal of the cast.

On September 27, 1976, the patient was transferred to the Rancho Los Amigos Hospital and had additional surgery on October 27: a dislodged Harrington rod was reimplemented and fusion of a site of pseudarthrosis was done. Postoperatively, a Milwaukee brace was used and, at the time of writing, there was no recurrence of the gastric volvulus.

Discussion

Acute gastric volvulus is rare because the stomach has so many ligament attachments and its mobility is so limited. The condition was first described by Berti in 1866. Since that time, the surgical literature has reported more than 200 cases associated with a congenital or developmental anomaly of the diaphragm, a diaphragmatic hernia, paralysis of the phrenic nerve, a gastric or duodenal ulcer, peritoneal adhesions, a gastric or pancreatic neoplasm, traction from a mobile spleen, gastric or colonic distention, and colonic diverticulosis^{1,4,5,9,11,12,14,16}. Roentgenograms of the stomach after a barium swallow are needed to make a diagnosis during the obstructive phase of gastric volvulus. In our patient, the volvulus was relieved by conservative measures, and subsequent gastrointestinal contrast studies were normal. We do not suggest that aortography be performed in all cases, but a differentiation of volvulus from the cast syndrome cannot be made absolutely without that study. The differentiation seems important because there is a significant mortality for each of these complications and particularly for those cases not properly responsive to conservative treatment. The surgical treatment for the two conditions is quite different: gastropexy for volvulus^{4,8,16} and division of the ligament of Treitz, duodenojejunostomy, or both for vascular compression^{3,7,10,15,17}.

We can speculate whether some reported cases of the cast syndrome where neither an upper gastrointestinal contrast study nor aortography was done might not be instances of unrecognized acute gastric volvulus. We cannot explain why gastric volvulus should develop in our patient and then recur despite a substantial weight gain. One of us (J. A. C.) reasoned that the high position of the left leaf of the diaphragm, often seen in scoliosis patients, may have been a factor, along with the prolonged recumbency and the plaster immobilization.

References

- BERANBAUM, S. L.; GOTTLIEB, CHARLES; and LEFFERTS, DAVID: Gastric Volvulus. Part III. Secondary Gastric Volvulus. *Am. J. Roentgenol.*, **72**: 625-638, 1954.
- BERTI, A.: Sigolare attortigliamento dell'esofago col duodeno seguito da rapida morte. *Gazz. med. Ital.*, **9**: 139, 1866.
- BISLA, R. S., and LOUIS, H. J.: Acute Vascular Compression of the Duodenum following Cast Application. *Surg., Gynec. and Obstet.*, **140**: 563-566, 1975.
- CAMPBELL, J. B.; RAPPAPORT, L. N.; and SHERKER, L. B.: Acute Mesentero-Axial Volvulus of the Stomach. *Radiology*, **103**: 153-156, 1972.
- COLE, B. C., and DICKINSON, S. J.: Acute Volvulus of the Stomach in Infants and Children. *Surgery*, **70**: 707-717, 1971.
- DORPH, M. H.: The Cast Syndrome. Review of the Literature and Report of a Case. *New England J. Med.*, **243**: 440-442, 1950.
- EVARTS, C. M.; WINTER, R. B.; and HALL, J. E.: Vascular Compression of the Duodenum Associated with the Treatment of Scoliosis. Review of the Literature and Report of Eighteen Cases. *J. Bone and Joint Surg.*, **53-A**: 431-444, April 1971.
- GOSIN, STEPHEN, and BALLINGER, W. F., II: Recurrent Volvulus of the Stomach. Report of a Case with Recurrence after Simple Decompression. *Am. J. Surg.*, **109**: 642-645, 1965.
- GOTTLIEB, CHARLES; LEFFERTS, DAVID; and BERANBAUM, S. L.: Gastric Volvulus. Part I. *Am. J. Roentgenol.*, **72**: 609-615, 1954.
- KAISER, G. C.; MCKAIN, J. M.; and SHUMACKER, H. B., JR.: The Superior Mesenteric Artery Syndrome. *Surg., Gynec. and Obstet.*, **110**: 133-140, 1960.
- KILCOYNE, R. F.; BABBITT, D. P.; and SAKAGUCHI, SHIMPEI: Volvulus of the Stomach. A Case Report. *Radiology*, **103**: 157-158, 1972.
- LEFFERTS, DAVID; BERANBAUM, S. L.; and GOTTLIEB, CHARLES: Gastric Volvulus. Part II. Idiopathic Gastric Volvulus. *Am. J. Roentgenol.*, **72**: 616-624, 1954.
- MANSBERGER, A. R., JR.; HEARN, J. B.; BYERS, R. M.; FLEISIG, NORBERT; and BUXTON, R. W.: Vascular Compression of the Duodenum. Emphasis on Accurate Diagnosis. *Am. J. Surg.*, **115**: 89-96, 1968.
- MYERSON, D. A.; MYERSON, P. J.; and LAWSON, J. P.: Antral Infracolic Volvulus of the Stomach. *J. Canadian Assn. Radiol.*, **26**: 128-131, 1975.
- REID, R. L., and GAMON, R. S., JR.: The Cast Syndrome. *Clin. Orthop.*, **79**: 85-88, 1971.
- STREMPLE, J. F.: A New Operation for the Anatomic Correction of Chronic Intermittent Gastric Volvulus. *Am. J. Surg.*, **125**: 360-363, 1973.
- WARNER, T. F. C. S.; SHORTER, R. G.; MCLLRATH, D. C.; and DUPRE, E. L., JR.: The Cast Syndrome. An Unusually Severe Case. *J. Bone and Joint Surg.*, **56-A**: 1263-1266, Sept. 1974.
- WAYNE, ELI; MILLER, R. E.; and EISEMAN, B.: Duodenal Obstruction by the Superior Mesenteric Artery in Bedridden Combat Casualties. *Ann. Surg.*, **174**: 339-344, 1971.